

Effect of levetiracetam on hepatic fibrosis in diabetic rats

Diyabetik sıçanlarda karaciğer fibrozisi üzerine levetirasetam etkisi

Yiğit Uyanıkgil,^{1,2} Tülay Akman,³ İbrahim Çavuşoğlu,⁴ Erkan Kısımalı,⁵ Dilek Taşkırın,⁶ Oytun Erbaş⁷

¹Department of Histology and Embryology, Medical Faculty of Ege University, İzmir, Turkey

²Cord Blood, Cell-Tissue Research and Application Center, Ege University, İzmir, Turkey

³Department of Medical Oncology, İzmir Tepecik Training and Research Hospital, İzmir, Turkey

⁴Department of Radiology, Kolan British Hospital, Lefkosa, Republic of Northern Cyprus

⁵Department of Radiology, Medical Faculty of Ege University, İzmir, Turkey

⁶Department of Physiology, Medical Faculty of Ege University, İzmir, Turkey

⁷Department of Physiology, Medical Faculty of İstanbul Bilim University, İstanbul, Turkey

ABSTRACT

Objectives: In our study we investigated the possible effects of levetiracetam (LEV) on hepatic fibrosis in streptozotocin (STZ) induced diabetic rats with histopathology, real-time elastography imaging technique. We also aimed to investigate the effects of LEV on oxidative stress markers.

Materials and methods: Diabetes was induced by intraperitoneal (i.p.) single dose injection of STZ (60 mg/kg). Twenty-one rats were randomly divided into three groups; control group, STZ group treated with 1 mL/kg/day saline (STZ+SP), and STZ group treated with 600 mg/kg/day LEV was administrated by i.p. for four weeks. All rats underwent a real-time elastography (strain-elasticity %). The liver sections are examined by histopathologically (liver fibrosis score). In addition, malondialdehyde, total antioxidant capacity, and glutathione levels were measured in plasma.

Results: Treatment with LEV significantly decreased liver fibrosis score and increased strain measurement % on the real-time elastography in diabetic rats. In addition, treatment with LEV significantly increased total antioxidant capacity, glutathione and malondialdehyde levels decreased in plasma of diabetic rats.

Conclusion: Levetiracetam has potential as a treatment for diabetic liver injury and hepatic fibrosis and can be a good candidate among new treatment options. In addition, real-time elastography is reliable imaging non-invasive technique for detecting hepatic fibrosis.

Keywords: Diabetes mellitus; levetiracetam; oxidative stress; real-time elastography.

ÖZ

Amaç: Bu çalışmada, streptozotocin (STZ) ile indüklenmiş diyabetik sıçanlardaki hepatik fibrozis üzerine levetirasetamın (LEV) pozitif etkilerinin histopatolojik ve gerçek zamanlı elastografik görüntüleme tekniği ile incelenmesi amaçlandı. Yine bu çalışmada LEV'nin oksidatif stres belirteçleri üzerine etkisi araştırıldı.

Gereç ve yöntemler: Diyabetik model, tek doz intraperitoneal (i.p.) STZ (60 mg/kg) enjeksiyonu ile yapıldı. Yirmi bir sıçan rastgele olarak üç gruba ayrıldı; kontrol grubu, STZ uygulaması yapıp 1 mL/kg/gün salin verilen grup (STZ+SP) ve STZ uygulanıp dört hafta boyunca 600 mg/kg/gün i.p LEV uygulanan grup. Tüm sıçanlar gerçek zamanlı elastografik yöntem ile incelendi (gerilme-elastikiyet yüzdesi). Karaciğerden alınan kesitler histopatolojik olarak değerlendirildi (karaciğer fibroz skor). Bunlara ek olarak, plazmadan malondialdehit, total antioksidant kapasite ve glutatyon seviyeleri ölçüldü.

Bulgular: Levetirasetam ile tedavi edilen diyabetik sıçanlarda karaciğer fibroz skorlamasında anlamlı bir azalma ve gerçek zamanlı elastografik gerilim-elastikiyet yüzdesinde artış saptandı. Bununla birlikte LEV tedavisinde diyabetik sıçanlarda total antioksidant kapasitesinin arttığı, glutatyon ve malondialdehitin plazma seviyelerinin azaldığı görüldü.

Sonuç: Levetirasetam, diyabetik karaciğer hasarı ve karaciğer fibrozisi için yeni tedavi seçenekleri arasında iyi bir aday olabilir. Buna ek olarak gerçek zamanlı elastografi, hepatik fibrozisin tespitinde non-invazif ve güvenilir bir görüntüleme bir tekniğidir.

Anahtar sözcükler: Diabetes mellitus; levetirasetam; oksidatif stres; gerçek zamanlı elastografi.

Received: February 11, 2015 **Accepted:** June 16, 2015

Correspondence: Yiğit Uyanıkgil, MD. Ege Üniversitesi Tıp Fakültesi Histoloji ve Embriyoloji Anabilim Dalı, 35100 Bornova, İzmir, Turkey.

Tel: +90 232 - 390 59 08 e-mail: yigit.uyanikgil@ege.edu.tr

Type 2 diabetes mellitus and hyperinsulinemia are closely associated with the development of fatty changes in the liver ranging from simple steatosis to steatohepatitis to advance liver disease such as hepatic fibrosis and cirrhosis.^[1,2] Despite extensive studies, the underlying mechanisms of these liver diseases still remain largely undefined. Evidence of oxidative stress with decreased antioxidant defenses has been found to be associated with hepatic fibrosis regardless of etiology and fibrosis progression rate.^[3,4]

Although there are few effective therapies used for the treatment of hepatic fibrosis, no drug has been approved as anti-fibrotic agent in humans so far.^[5,6] The benefit of the agents reducing the oxidative stress, inflammation and immune response were determined in the previous studies and to date, only limited antifibrogenic treatment options are available to protect hepatocytes from oxidative stress and reduce inflammatory damage. In the previous studies they have shown that different types of antioxidants could attenuate the complications of diabetes including fatty liver diseases and fibrosis.^[7-9]

Levetiracetam (LEV) is a commonly used antiepileptic drug that acts as a histone deacetylase inhibitor and an inhibitor of high-voltage activated N-type calcium channels. The recent evidence shows that the drug has anti-inflammatory and antioxidative effects.^[10-12] In a previous experimental study the neuroprotective effects of LEV by reducing the level of oxidative stress markers and anti-inflammatory cytokines were determined.^[10] On account of this results LEV may be a promising candidate for treating other inflammatory diseases such as hepatic fibrosis.

In this present study we aimed to investigate the possible effects of LEV on hepatic fibrosis in streptozotocin (STZ) induced diabetic rats with histopathology and real-time elastography imaging technique. We also aimed to investigate the effects of LEV on oxidative stress.

MATERIALS AND METHODS

Animals

In this study 21 male Sprague Dawley albino mature rats at eight weeks, weighing 200-220 g, were used. Animals were fed ad libitum and housed

impairs in steel cages having a temperature-controlled environment (22 ± 2 °C) with 12-h light/dark cycles. The experimental procedures were approved by the Committee for Animal Research of Ege University. All animal studies are strictly conformed to the Animal Experiment Guidelines of the Committee for Human Care.

Experimental protocol

Diabetes was induced by intraperitoneal (i.p) injection of STZ (Sigma-Aldrich, Inc.; Saint Louis, MO, USA) (60 mg/kg in 0.9% NaCl, adjusted to a pH 4.0 with 0.2M sodium citrate) for 14 rats. No drug was administered to the remainder of rats (n=7) (Control group). Diabetes was verified after 24 hours by evaluating blood glucose levels with the use of glucose oxidase reagent strips (Boehringer-Mannheim Corp, Indianapolis, IN). The rats with blood glucose levels 250 mg/dL and higher were included in this study. We waited 21 days for the development of diabetes-related microvascular complications.^[13] Then, 14 diabetic rats were randomly divided into two groups; STZ group treated with 1 mL/kg saline (STZ+SP) (n=7), and STZ group treated with 600 mg/kg/day LEV (Keppra falcon, UCB, Greece) (STZ+LEV) (n=7) was administrated by i.p for four weeks.

Histopathological examination of liver

For histological studies, all animals were anesthetized by an i.p. of ketamin (40 mg/kg)/xylazine (4 mg/kg) and perfused with 200 mL of 4% formaldehyde in 0.1 M phosphate-buffer saline (PBS). Formalin-fixed liver sections (4 μ m) were stained with Masson's trichrome. All sections were photographed with Olympus C-5050 digital camera mounted on Olympus BX51 microscope (Olympus optical Co. Ltd., Hatagaya, Shibuya-ku, Tokyo, Japan).

Morphological analysis was assessed by computerized image analysis system (Image-Pro Express 1.4.5, Media Cybernetics, Inc. USA) on 10 microscopic fields per section examined at a magnification of x40, with the observer blind to the study group. Histological lesions (fibrosis) were evaluated according to the following scale: 0= absent; 1= mild (involving 10% per microscopic field); 2= moderate (>11 and 25%); 3= severe (>26 and 50%) or 4= very severe (>50%).

Real-time elastography

Elastography measures mechanically induced deformation (strain) of structures in the B mode image to quantify the elasticity of the tissue. By measuring the tissue strain induced by compression, it is possible to estimate the tissue hardness.

Transabdominal real-time elastography was proposed as a new method for noninvasive staging of liver fibrosis relative tissue elasticity is calculated and displayed as a color overlay of the conventional B-mode image.

Stiffer tissue (low elasticity) structures are displayed in blue, while the more easily deformed tissues (high elasticity) are in red. If there is an increase in liver fibrosis is reduced strain (elasticity), so the color turns blue and strain measured the percent (%) value is reduced.^[14,15]

Strain (elasticity) measurement

All groups underwent real-time elastography (EUB-8500, Hitachi Hi-Vision Avius; 9-MHz probe, Japan). The rats were examined in a supine position. An area was chosen where the liver tissue was at least 3 cm thick and was free of large blood vessels. Strain measurements of circular ROI (Region of Interest) were used. ROI was placed 0.5 cm lateral to the portal vein.

The examination was performed with a 9-MHz transducer because, similar to B-mode imaging, higher frequencies allow better analysis of areas close to the transducer, and assessment of real-time elastography is optimized by the manufacturer on superficial tissues. The measurement depth was between 10 and 15 mm (mean, 12 mm) with a 80-90 mm² area of measurement (mean, 85 mm²). 5-10 minutes per rats (Figure 1).

Measurement of lipid peroxidation

Lipid peroxidation was determined in plasma samples by measuring malondialdehyde (MDA) levels as thiobarbituric acid reactive substances.^[16] Briefly, trichloroacetic acid and thiobarbituric acid reactive substances (TBARS) reagent were added to the plasma samples, then mixed and incubated at 100 °C for 60 min. After cooling on ice, the samples were centrifuged at 3000 rpm for 20 min and the absorbance of the supernatant was read at 535 nm. Malondialdehyde levels were

calculated from the standard calibration curve using tetraethoxypropane and expressed as μM .

Measurement of plasma total antioxidant capacity (TAC)

Plasma total antioxidant capacity was measured by ferric reducing antioxidant power (FRAP) assay according to Benzie and Strain.^[17] Briefly, the FRAP reagent (sodium-acetate, tripyridiltriazine in hydrochloric acid and ferric chloride) pre-warmed to 37 °C were mixed with plasma; the absorbance was read after 4 min at 593 nm. A calibration curve was prepared by substituting the sample with freshly prepared of ascorbic acid solution (100-1000 μM).

Measurement of plasma glutathione (GSH) levels

Glutathione content in plasma samples was measured spectrophotometrically according to Ellman's method.^[18] In this method, thiols interact with 5,5'-dithiobis-(2-nitrobenzoic acid) (DTNB) and form a colored anion with maximum peak at 412 nm. Glutathione levels were calculated from the standard calibration curve and expressed as μM .

Statistical analysis

All quantitative data were analyzed by using non-parametric (Mann-Whitney U) test. Student's t test was used to evaluate the differences between the groups. Data are presented as mean values \pm standard error of the mean (SEM). *P* values of 0.05 or less were regarded as statistically significant.

RESULTS

Figure 1 shows tissue elasticity distribution displayed as a color overlay of the conventional B-mode image. Stiffer or fibrotic tissue (low elasticity) structures are displayed in blue, while the more easily deformed or low fibrotic tissues (high elasticity) are in red. If there is an increase in liver fibrosis is reduced strain (elasticity), so the color turns blue and strain measured the percent (%) value is reduced.

Figure 2 shows histopathological sections of control rat liver and LEV-treated diabetic rat liver induced by STZ. The liver histopathology of the STZ+SP group showed significantly higher liver fibrosis score when compared with the control group ($p < 0.001$). We also observed notably

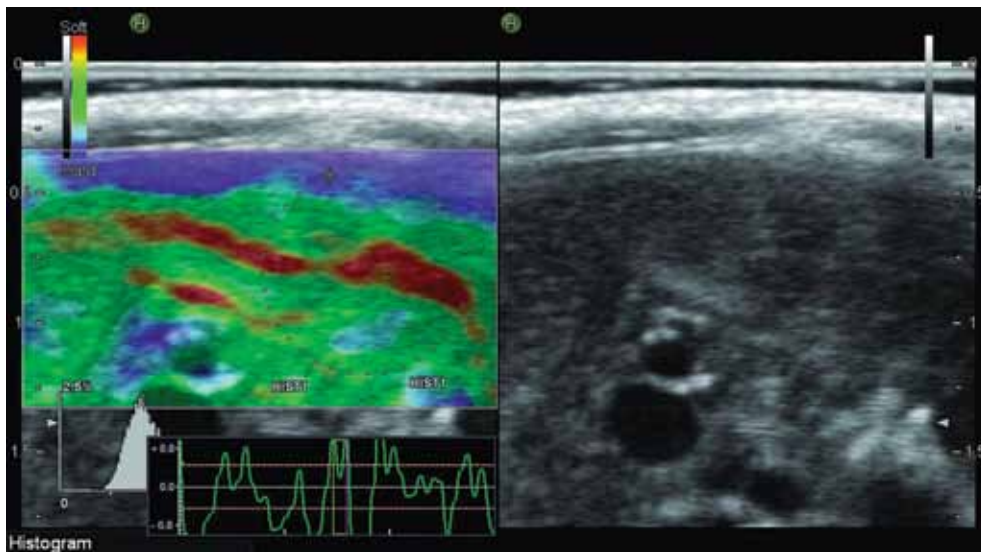


Figure 1. Tissue elasticity distribution displayed as a color overlay of the conventional B-mode image.

reduced liver fibrosis score in the STZ+LEV group when compared with the STZ+SP group ($p < 0.05$). The STZ+SP group showed significantly decreased strain on the real-time elastography when compared with control the group ($p < 0.001$). We also observed notably

increased strain in the STZ+LEV group when compared with the STZ+SP group ($p < 0.001$).

Table 1 shows the results of liver fibrosis score and strain measurement of control rat liver and diabetic rat liver induced STZ.

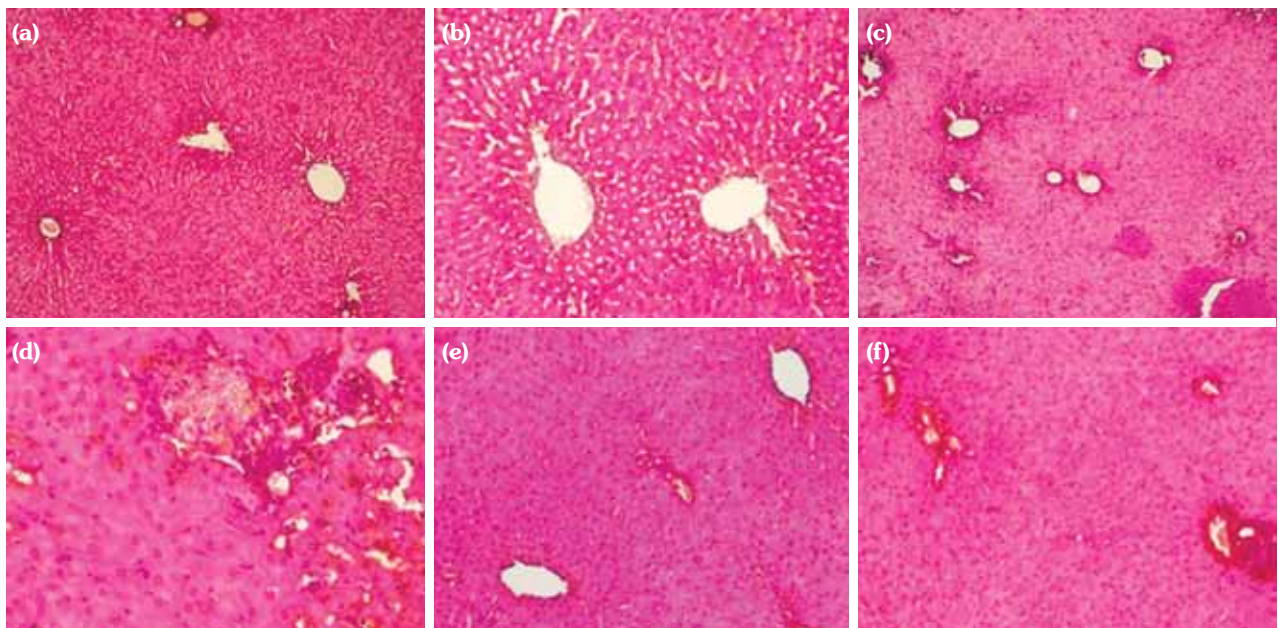


Figure 2. Histopathological assessment of control rat and levetiracetam treated diabetic rat induced by streptozotocin. The liver sections were stained with Masson's trichrome. Normal liver tissue were shown in control group (a; x10, b; x20). Perivascular (portal and central area) fibrotic alterations and inflammation were shown in diabetic rats (STZ+SP group) (c; x10, d; x40). Regression of fibrotic alteration and inflammation were shown in levetiracetam treated diabetic rats (LEV+STZ group) compared to STZ+SP group (e; x20, f; x20).

Table 1. The results of histopathological examination (Liver fibrosis score) and real-time elastography (Strain-elasticity) of control rat liver and diabetic rat liver induced by streptozotocin

Group	Liver fibrosis score	Strain elasticity (%)
	Mean±SD	Mean±SD
Control	0.8±0.37	83.1±1.8
Streptozotocin+serum physiological	3.6±0.24*	31.8±3.0*
Streptozotocin+levetiracetam	2.4±0.50†	50.1±2.3‡

SD: Standard deviation; * p<0.001, different from control group; † p<0.05, different from streptozotocin+serum physiological group; ‡ p<0.001, different from streptozotocin+serum physiological group.

Table 2. The results of glutathione, total antioxidant capacity, and malondialdehyde levels in the plasma of diabetic rats induced by streptozotocin

Group	GSH (μM)	TAC (μM)	MDA (μM)
	Mean±SD	Mean±SD	Mean±SD
Control	14.15±1.41	133.08±6.9	0.12±0.01
Streptozotocin+serum physiological	2.40±0.62#	44.53±6.58#	0.335±0.034#
Streptozotocin+levetiracetam	6.20±0.59*	95.72±13.13*	0.215±0.005*

GSH: Glutathione; TAC: Total antioxidant capacity; MDA: Malondialdehyde; # p<0.000, different from control group; * p<0.001, different from streptozotocin+serum physiological group.

Table 2 shows the results of GSH, TAC, and MDA levels in the plasma of diabetic rats induced STZ. The STZ+SP group showed significantly decreased total TAC, GSH and increased MDA levels when compared with the control group. The STZ+LEV group showed significantly increased total TAC, GSH and decreased MDA levels when compared with the STZ+SP group.

DISCUSSION

In this present study we have shown the protective antioxidant effects of LEV on hepatic fibrosis in STZ induced diabetic rats with histological examination, real-time elastography imaging technique and measurement of oxidative and antioxidative markers. Our result was consistent with the other studies and showed that type 2 DM and hyperglycemia are major risk factors for diabetic hepatic injury.^[9]

Pathogenesis of diabetic liver injury comprises two steps. The first step is thought to be insulin resistance increasing the transport of fatty acids from adipose tissue to the liver and causes accumulation of fat in the hepatocytes. In the second step increased oxidative stress and production of inflammatory cytokines lead to the hepatocellular injury and subsequently progress to hepatic fibrosis.^[19,20] Pro-inflammatory and pro-fibrogenic role of oxidative stress products play a critical role in this step.^[21] In the previous studies,

increased levels of lipid peroxidation products and oxidative stress markers and decreased levels of antioxidant enzymes are found in nonalcoholic steatohepatitis (NASH) patients.^[22,23] In prior reports the protective effect of antioxidants and stimulation of collagen production and hepatic fibrogenesis by oxidative stress were shown.^[3,24] Oxidative stress-related molecules may act as mediators and trigger the events responsible for the progression of hepatic fibrosis.^[4] Reactive oxygen species (ROS) trigger formation of cytokines and growth factors leading to inflammatory response and eventually liver damage.

Currently, liver biopsy is still the gold standard for determining hepatic fibrosis. In spite of this, it is an invasive and extremely uncomfortable procedure, and sometimes may result with serious complications.^[25,26] Besides, significant intra- and interobserver variability is reported in the pathologic evaluation of the specimens.^[27,28] As a consequence, the evaluation of non-invasive methods for liver fibrosis assessment has become important in recent researches. Real-time elastography is a method used for the detection of focal lesions in the breast, thyroid gland, and prostate gland.^[29] In a previous study, they had shown that real-time elastography can be used for the measurement of liver fibrosis in patients with chronic viral hepatitis.^[14] In a recent study, Lin et al.^[30] used real-time elastography as a reliable imaging technique for quantitative evaluation of

hepatic fibrosis induced by dimethylnitrosamine (DMN) in rats. They compared the results of real-time elastography [acquire area ratio of low-strain region (% AREA) and liver fibrosis index] with the stage of liver fibrosis and grade of necroinflammatory pathologically. They determined that the values of liver fibrosis index and low-strain region were both increased with liver fibrosis stage. They found a certain correlation between liver fibrosis index and liver fibrosis stage, so as low-strain region and liver fibrosis stage. In this present study, perivascular fibrotic alterations in the liver was determined in diabetic rats histopathologically and lower strain measurement was found by using real-time elastography.

Levetiracetam is an antiepileptic drug which has been proved to have antioxidative and antiinflammatory efficacy.^[10-12] It was demonstrated that besides the antiepileptic efficiency of the drug LEV has neuroprotective effects associated with the reduction of lipid peroxidation, and the increase of the level of endogenous antioxidants.^[11] Levetiracetam also regulates the influx of calcium into the cells, and modulates membrane depolarization and prevents irreversible cellular damage.^[31-33] In this present study we determined the protective antioxidant effects of LEV on hepatic fibrosis. Significant increases were detected in the serum levels of GSH and TAC while there was a significant decrease in the serum levels of MDA in the LEV+STZ group. Much evidence supports the association between oxidant injury and hepatic fibrogenesis.^[34] It was reported that a well known antioxidant molecule vitamin E, reduced the level of lipid peroxidation molecules in the liver of STZ-diabetic rats and prevented the development of diabetic hepatic injury.^[8] Another well-known antioxidant molecule melatonin was used in a study and significant decrease in an oxidative stress parameter, MDA, in brain, liver and kidney was determined.^[8] In another study by using angiotensin converting enzyme inhibitor to protect liver damage in STZ-induced diabetic rats, they had shown the negative correlation between liver tissue fibrosis and glutathione related antioxidant defenses.^[9]

As a result we showed that when compared with histological investigation, real-time elastography is a reliable imaging technique for

detecting hepatic fibrosis. Taken together the mechanism of action of LEV and pathogenesis of diabetic liver injury, LEV has potential as a treatment for diabetic liver injury and hepatic fibrosis and can be a good candidate among new treatment options. Given the scope of the problem more evidence is needed for the effectiveness and safety of this drug and future prospective and randomized studies will be needed to confirm recommendations.

Declaration of conflicting interests

The authors declared no conflicts of interest with respect to the authorship and/or publication of this article.

Funding

The authors received no financial support for the research and/or authorship of this article.

REFERENCES

1. Stone BG, Van Thiel DH. Diabetes mellitus and the liver. *Semin Liver Dis* 1985;5:8-28.
2. Keeffe EB, Adesman PW, Stenzel P, Palmer RM. Steatosis and cirrhosis in an obese diabetic. Resolution of fatty liver by fasting. *Dig Dis Sci* 1987;32:441-5.
3. Di Sario A, Candelaresi C, Omenetti A, Benedetti A. Vitamin E in chronic liver diseases and liver fibrosis. *Vitam Horm* 2007;76:551-73.
4. Parola M, Robino G. Oxidative stress-related molecules and liver fibrosis. *J Hepatol* 2001;35:297-306.
5. Svegliati-Baroni G, De Minicis S, Marzioni M. Hepatic fibrogenesis in response to chronic liver injury: novel insights on the role of cell-to-cell interaction and transition. *Liver Int* 2008;28:1052-64.
6. Pinzani M, Rombouts K. Liver fibrosis: from the bench to clinical targets. *Dig Liver Dis* 2004;36:231-42.
7. Wu YG, Xia LL, Lin H, Zhou D, Qian H, Lin ST. Prevention of early liver injury by breviscapine in streptozotocin-induced diabetic rats. *Planta Med* 2007;73:433-8.
8. Baydas G, Canatan H, Turkoglu A. Comparative analysis of the protective effects of melatonin and vitamin E on streptozocin-induced diabetes mellitus. *J Pineal Res* 2002;32:225-30.
9. de Cavanagh EM, Inserra F, Toblli J, Stella I, Fraga CG, Ferder L. Enalapril attenuates oxidative stress in diabetic rats. *Hypertension* 2001;38:1130-6.
10. Stettner M, Dehmel T, Mausberg AK, Köhne A, Rose CR, Kieseier BC. Levetiracetam exhibits protective properties on rat Schwann cells in vitro. *J Peripher Nerv Syst* 2011;16:250-60.
11. Ueda Y, Doi T, Takaki M, Nagatomo K, Nakajima A, Willmore LJ. Levetiracetam enhances endogenous antioxidant in the hippocampus of rats: in vivo evaluation by brain microdialysis combined with ESR

- spectroscopy. *Brain Res* 2009;1266:1-7.
12. Gibbs JE, Walker MC, Cock HR. Levetiracetam: antiepileptic properties and protective effects on mitochondrial dysfunction in experimental status epilepticus. *Epilepsia* 2006;47:469-78.
 13. Coppey LJ, Davidson EP, Dunlap JA, Lund DD, Yorek MA. Slowing of motor nerve conduction velocity in streptozotocin-induced diabetic rats is preceded by impaired vasodilation in arterioles that overlie the sciatic nerve. *Int J Exp Diabetes Res* 2000;1:131-43.
 14. Friedrich-Rust M, Ong MF, Herrmann E, Dries V, Samaras P, Zeuzem S, et al. Real-time elastography for noninvasive assessment of liver fibrosis in chronic viral hepatitis. *AJR Am J Roentgenol* 2007;188:758-64.
 15. Kanamoto M, Shimada M, Ikegami T, Uchiyama H, Imura S, Morine Y, et al. Real time elastography for noninvasive diagnosis of liver fibrosis. *J Hepatobiliary Pancreat Surg* 2009;16:463-7.
 16. Demougeot C, Marie C, Beley A. Importance of iron location in iron-induced hydroxyl radical production by brain slices. *Life Sci* 2000;67:399-410.
 17. Benzie IF, Strain JJ. Ferric reducing/antioxidant power assay: direct measure of total antioxidant activity of biological fluids and modified version for simultaneous measurement of total antioxidant power and ascorbic acid concentration. *Methods Enzymol* 1999;299:15-27.
 18. Ellman GL. Tissue sulfhydryl groups. *Arch Biochem Biophys* 1959;82:70-7.
 19. Day CP, James OF. Steatohepatitis: a tale of two "hits"? *Gastroenterology* 1998;114:842-5.
 20. Neuschwander-Tetri BA, Caldwell SH. Nonalcoholic steatohepatitis: summary of an AASLD Single Topic Conference. *Hepatology* 2003;37:1202-19.
 21. Clark JM, Diehl AM. Nonalcoholic fatty liver disease: an underrecognized cause of cryptogenic cirrhosis. *JAMA* 2003;289:3000-4.
 22. Maiese K, Morhan SD, Chong ZZ. Oxidative stress biology and cell injury during type 1 and type 2 diabetes mellitus. *Curr Neurovasc Res* 2007;4:63-71.
 23. Leclercq IA, Da Silva Morais A, Schroyen B, Van Hul N, Geerts A. Insulin resistance in hepatocytes and sinusoidal liver cells: mechanisms and consequences. *J Hepatol* 2007;47:142-56.
 24. Das KS, Balakrishnan V, Mukherjee S, Vasudevan DM. Evaluation of blood oxidative stress-related parameters in alcoholic liver disease and non-alcoholic fatty liver disease. *Scand J Clin Lab Invest* 2008;68:323-34.
 25. Bravo AA, Sheth SG, Chopra S. Liver biopsy. *N Engl J Med* 2001;344:495-500.
 26. Castéra L, Nègre I, Samii K, Buffet C. Pain experienced during percutaneous liver biopsy. *Hepatology* 1999;30:1529-30.
 27. Bedossa P, Dargère D, Paradis V. Sampling variability of liver fibrosis in chronic hepatitis C. *Hepatology* 2003;38:1449-57.
 28. Regev A, Berho M, Jeffers LJ, Milikowski C, Molina EG, Pyrsopoulos NT, et al. Sampling error and intraobserver variation in liver biopsy in patients with chronic HCV infection. *Am J Gastroenterol* 2002;97:2614-8.
 29. Giuseppetti GM, Martegani A, Di Cioccio B, Baldassarre S. Elastosonography in the diagnosis of the nodular breast lesions: preliminary report. *Radiol Med* 2005;110:69-76.
 30. Lin SH, Ma JJ, Zhang H, Ding H, Yu Q, Zhu HG, et al. Real-time elastography for quantitative assessment of liver fibrosis in a rat model. *Zhonghua Gan Zang Bing Za Zhi* 2012;20:386-9. [Abstract]
 31. Niespodziany I, Klitgaard H, Margineanu DG. Levetiracetam inhibits the high-voltage-activated Ca(2+) current in pyramidal neurones of rat hippocampal slices. *Neurosci Lett* 2001;306:5-8.
 32. Pisani A, Bonsi P, Martella G, De Persis C, Costa C, Pisani F, et al. Intracellular calcium increase in epileptiform activity: modulation by levetiracetam and lamotrigine. *Epilepsia* 2004;45:719-28.
 33. Madeja M, Margineanu DG, Gorji A, Siep E, Boerrigter P, Klitgaard H, et al. Reduction of voltage-operated potassium currents by levetiracetam: a novel antiepileptic mechanism of action? *Neuropharmacology* 2003;45:661-71.
 34. Poli G, Parola M. Oxidative damage and fibrogenesis. *Free Radic Biol Med* 1997;22:287-305.